
CASE REPORT

Acute Appendicitis Leading to Small and Large Bowel Obstruction

AZHAR BASHIR, MEHMOOD UL HAQ FAROOQI, FAISAL BASHIR, AMER RIAZ BHUTTA, ATIF PERVEZ, EJAZ IQBAL, FARA HASSA, MA CHEEMA

SUMMARY

Intestinal obstruction is a common surgical emergency caused by varied conditions. Obstruction of large intestine caused by appendicitis is extremely rare with very few cases reported in literature. The diagnosis of such a condition is possible only on table. Every emergency surgeon needs to be aware of such a possibility. We report a case of a 37 year old female presenting with classical features of intestinal obstruction, abdominal pain and absolute constipation for last 3 days. On laparotomy small and large obstructed bowel was seen and appendix was found to be the cause. Although we obtained a history of appendicitis in this patient, it was not correlated to the present condition due to the rarity of such a scenario. We reviewed literature to find similar cases reported in the past.

Key words: Acute appendicitis, intestinal obstruction.

INTRODUCTION

Intestinal obstruction is a common surgical emergency caused by varied conditions. Appendix as a cause of intestinal obstruction is uncommon and not usually suspected. Although it was described as early as 1901, very few reports are available which do a comprehensive review. Pre-operatively it is very difficult to diagnose this condition. The diagnosis is always made at the time of laparotomy. The treatment varies from appendectomy to intestinal resection or even right hemicolectomy.

CASE REPORT

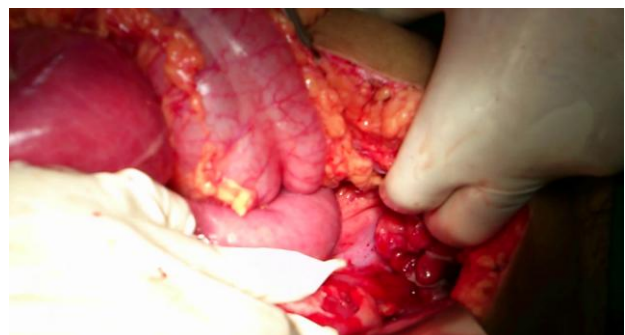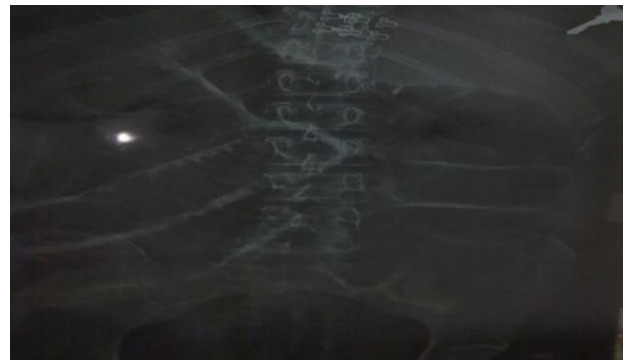
A 37 year old female presented with abdominal pain for 3 days, absolute constipation for last 3 days, abdominal distension for last 1 day and vomiting for 10 hours. On examination he was afebrile and vitals were stable.

Vitals: BP= 110/70mmhg, pulse=102/min, temp=afebrile, R/R= 20/min. Abdomen: distended, tense, tender abdomen; bowel sounds absent; Per rectal examination was done to rule out fecal impaction or mass and it was found to be normal. Systemic examination was unremarkable. Routine blood investigations were normal except for leucocytosis of 17,400 with neutrophilia. Plain X-ray of abdomen showed dilated small and large gut loops. USG abdomen revealed thickened bowel wall with absent peristalsis.

Preoperatively patient was kept nil per oral through nasogastric aspiration. She was started on

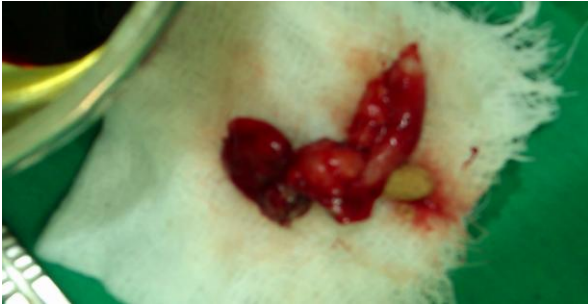intravenous fluids and prophylactic intravenous antibiotics. On reassessment patient's condition remained unaltered. A diagnosis of mechanical intestinal obstruction of unknown etiology was made and she was scheduled for emergency laparotomy.

Exploratory laparotomy and appendectomy done for perforated appendix. Abdomen was opened with a midline vertical incision. Findings were 200cc reactionary fluid, Grossly dilated small and large gut loops, Perforated appendix with fecolith and mass formation that was adherent to rectum and ileum leading to small and large bowel obstruction.



Department of Surgery, K. E. Medical University/Mayo Hospital, Lahore.

Correspondence to Dr. Amar Riaz Bhutta, Associate Professor, Email: arbsurgeon@gmail.com.



DISCUSSION

Appendicitis causing intestinal obstruction was described as early as 1901, when Lucius Hotchkiss read at the meeting of New York surgical society, three successful surgeries for intestinal obstruction due to appendicitis¹. In 1908, Forbes Hawks divided them into mechanical, septic and a combination of the two². Adynamic type of intestinal obstruction is the most common type is due to the local paralytic ileus occurring as a result of appendicular inflammation spreading to the adjacent bowel wall, seen in 1-5% of appendicitis.

Mechanical intestinal obstruction without strangulation occurs as a result of kinking, compression or traction of the small bowel trapped in an appendicular mass or abscess. These can be managed conservatively as the obstruction should resolve with the resolution of the mass. However in some cases, minimal obstruction may persist which can turn into acute intestinal obstruction when a secondary pathology occurs months to years later³. The first case of small bowel strangulation caused by appendix was described by Naumon in 1963⁴. Strangulation can be due to the appendix wrapping around the base of a bowel loop, or when inflamed appendix adheres to caecum, small intestine or posterior peritoneum and a part of the bowel herniates through the gap. This is a rare occurrence with only ten other cases reported in literature^{5,6}, however in our case bowel wall was viable and there was no pus in the abdominal cavity and we could not find any literature or case report of whole small and large bowel obstruction due to acute appendicitis.

Intestinal obstruction occurring as a result of mesenteric ischemia produced by appendix is the rarest type with a sole case described by Gupta S. in 1969⁷. As to why appendix would adhere to adjacent structures, we have to know that the appendix is a mobile organ with many variations in its normal position. During the initial event of appendicular inflammation, it would get adhered to surrounding structures producing various pathologies mentioned

above. Increased length of appendix logically seems to predispose to such an event³.

Although the pathology may vary, clinically it is not possible to determine the exact type of intestinal obstruction present. Clinically these patients can be classified into two types:

1) In this group of patients, intestinal obstruction occurs during the phase of active appendicitis. Hence the cause is likely to be mechanical or adynamic.

2) Patients with Acute intestinal obstruction, on evaluation/laparotomy found to have appendicitis as the cause. In this group, there may or may not be a history of appendicitis. Intestinal obstruction dominates the clinical picture and may completely obscure the underlying appendicular disease. Appendicitis should therefore be considered in cases of mechanical intestinal obstruction of unknown cause, especially in the elderly. As in our case we suspected mechanical cause of obstruction and appendix stuck to rectum was found to be the cause.

Role of CT in detecting appendix as the cause of intestinal obstruction is questionable. During the phase of active appendicular inflammation there may be appropriate CT findings. However these findings may not be present in patients who develop intestinal obstruction after the resolution of appendicitis. Thus pointing out appendix as the cause would not be possible. However CT is very useful to detect bowel ischemia, intestinal obstruction and ascites when present. In case of intestinal obstruction without known cause, as with the second group, midline vertical incision is definitely the approach of choice.

There is no material available as to the role of laparoscope either with the diagnosis or management of intestinal obstruction due to appendicitis. It may be useful since it is diagnostic as well as therapeutic. There is less tissue handling; better cosmesis and a shorter post op stay .

Nobel⁹ and Zaslow¹⁰ emphasized the danger in rigidly adhering to the concept of postoperative paralytic ileus in patients with peritonitis secondary to appendicitis, but they did not mention acute appendicitis as a cause of mechanical small bowel obstruction.

Smith¹¹ is the only author who associated mechanical obstruction with acute perforative appendicitis. In his series of 3,418 cases of appendicitis from the Los Angeles County Hospital there were 31 deaths. Eight patients who died had a preoperative diagnosis of small bowel obstruction and in five the obstruction was mechanical.

CONCLUSION

Although the pathology may vary, clinically it is not possible to determine the exact type of intestinal

obstruction present. Clinically the presentation may be predominantly appendicitis or predominantly intestinal obstruction. Midline vertical incision would be the approach of choice whenever features of intestinal obstruction predominate, even if appendicitis is known to be the etiological agent. Whenever there is intestinal obstruction associated with acute appendicitis, it may not always be Adynamic and the rarer and more dangerous forms should always be kept in mind.

REFERENCES

1. Hotchkiss LuciusW: Acute intestinal obstruction following appendicitis. a report of three cases successfully operated upon. *Ann Surg* 1901, 34:660-677
2. Forbes Hawkes: The prevention of intestinal obstruction following operation for appendicitis. *Ann Surg* 1909, 49:192-207.
3. Croome RRM, Knox J: Large bowel obstruction with acute appendicitis. *Can Med Assoc J* 1959, 70:681.
4. Naumon ID: Two cases of strangulation of the small intestine in the loop of the appendix. *Khirurgiia Mosk* 1963, 39:130-132.
5. Srivatsan M: Intestinal obstruction caused by a long appendix ensnaring a loop of ileum. *J med Ind Ass* 1964, 43:400-401.
6. Paliwal YD, Singh RP: An unusual complication of appendix (intestinal obstruction)--case report. *Indian J Surg* 1969, 31:288.
7. Gupta S, Vaidya MP: Mechanical small bowel obstruction caused by acute appendicitis. *Am Surg* 1969, 35:670-674.
8. Assenza M, Ricci G: Mechanical small bowel obstruction due to an inflamed appendix wrapping around the last loop of ileum. *G Chir* 2005, 26:261-266.
9. Noble, T. B.: Paralytic Ileus From Peritonitis After Appendicitis. *Amer. J. Surg.*, 84:419, 1952.
10. Zaslow, J.: Early Postoperative Mechanical Obstruction Following the Removal of a Ruptured Gangrenous Appendix. *Amer. J. Surg.*, 65:276, 1944.
11. Smith, W. R.: Intestinal Obstruction Complicating Acute Perforative Appendicitis. *Calif. Med.*, 87:231, 1957.